NEOPLASIAS

DR RONALD H. MENDOZA CHOQUE
FELLOWSHIP 1ER AÑO
INEN
ron543210@hotmail.com

DEFINICION

Neoplasia = Nuevo Crecimiento

- **Una masa anormal de tejido que prolifera en forma excesiva y sin coordinación con el tejido normal y persiste en su crecimiento aún después de cesar el estímulo que provocó el cambio, compitiendo con células y tejidos normales respecto a sus necesidades metabólicas**

- Su nutrición depende del huésped
- Autónomo
- Clonalidad

TUMOR: Aumento de volumen de un tejido producido por edema, hemorragia, granuloma, neoplasia, etc.

CÁNCER: Crecimiento tisular producido por la proliferación continua de células anormales con capacidad de invasión y destrucción de otros tejidos.

PARÉNQUIMA: Células transformadas o neoplásicas responsables de la conducta biológica del tumor.

ESTROMA: Células no neoplásicas que constituyen el tejido conectivo vasos sanguíneos, linfáticos, etc; imprescindible para el crecimiento del tumor.

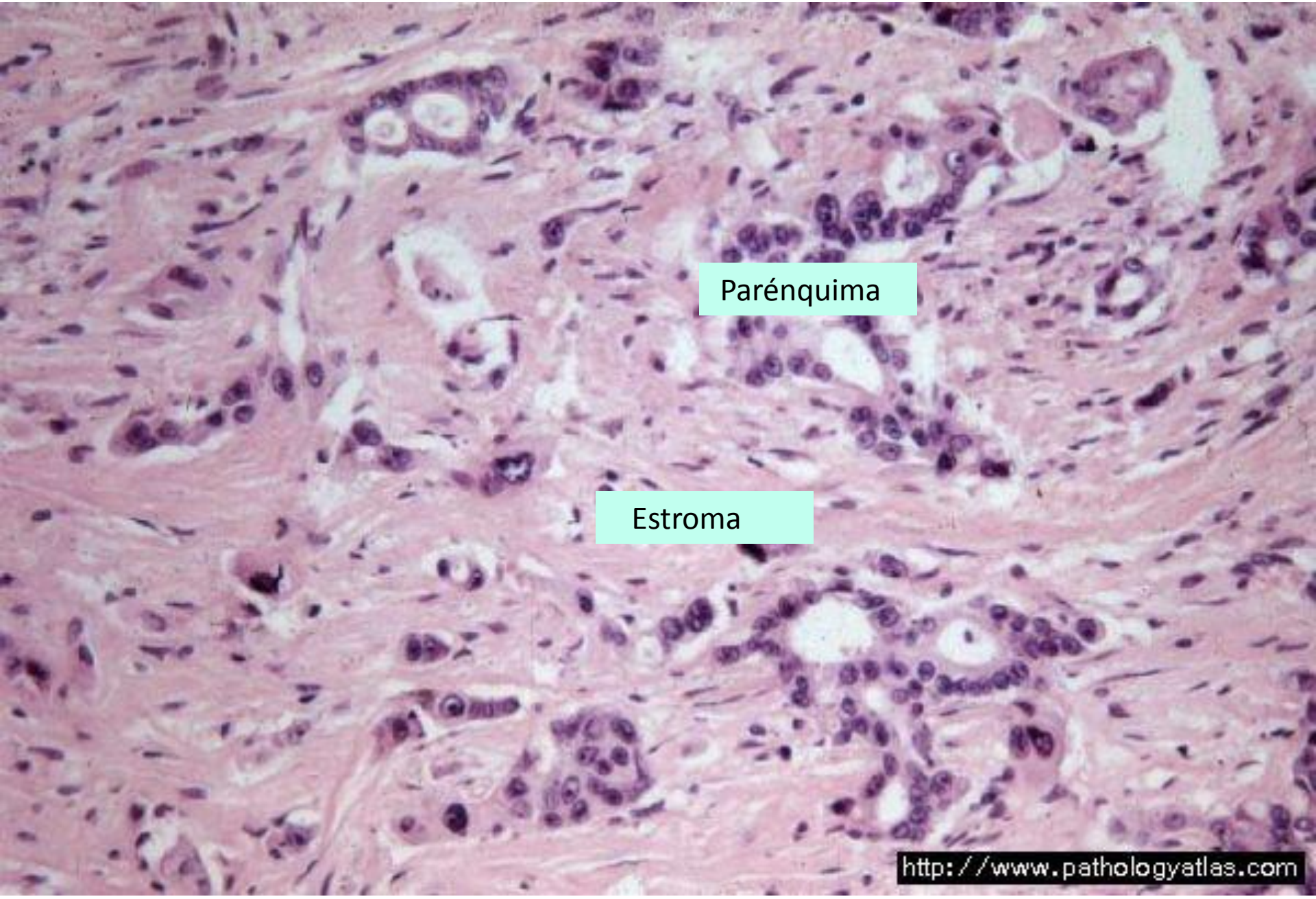
Parénquima
Estroma
http://www.pathologyatlas.com

CLASIFICACIÓN:

Epitelial: Escamoso, glandular, transicional, etc.

Mesenquimal: Músculo liso, músculo estriado, fibroso, hueso, etc.

Nervioso: Gliales, neuronas, nervios, etc.

Linfoproliferativo: Linfocitos, células plasmáticas, etc.

Endotelial, Embrionarios, etc.

BENIGNOS / MALIGNOS

NOMENCLATURA:

BENIGNOS: **"oma"**

- Adenoma, papiloma, cistoadenoma. Pólipo.
- Fibroma, osteoma, leiomioma, condroma, etc.
- Schwannoma, neurofibroma, etc.

MALIGNOS: **"carcinoma" / "sarcoma"**

- Adenocarcinoma, carcinoma escamoso, carcinoma de células transicionales.
- Fibrosarcoma, osteosarcoma, leiomiosarcoma.

- Schwannoma maligno, meningioma maligno, etc.
- Linfoma, seminoma, hepatoma, astrocitoma, melanoma, etc.

TUMORES BENIGNOS:

- Solo crecen hasta un determinado tamaño
- Normalmente no crecen muy rápido
- No destruyen células normales
- No se propagan al tejido que los rodea
- Normalmente no producen efectos secundarios graves
- Por lo general crecen de forma ordenada

TUMORES MALIGNOS:

- LA MAYORÍA CRECE RAPIDAMENTE
- CRECEN ILIMITADAMENTE
- PUEDEN INVADIR Y DESTRUIR ESTRUCTURAS ADYACENTES
- PUEDEN PROPAGARSE A SITIOS DISTANTES (METÁSTASIS)
- PRESENTAN UN AMPLIO MARGEN DE DIFERENCIACIÓN
- PUEDEN PROVOCAR LA MUERTE

TUMORES BENIGNOS

NOMBRE DE CÉLULA DE PROCEDENCIA+“OMA”

- FIBROBLASTOS ➡ FIBROMA
- PATRÓN GLANDULAR ➡ ADENOMA
- MASAS QUÍSTICAS ➡ CISTOADENOMA
- MASA QUISTICA CON PAPILAS EN SU INTERIOR ➡ CISTOADENOMA PAPILAR
- VERRUCOSA, DIGITIFORME SOBRE EPITELIO ➡ PAPILOMA

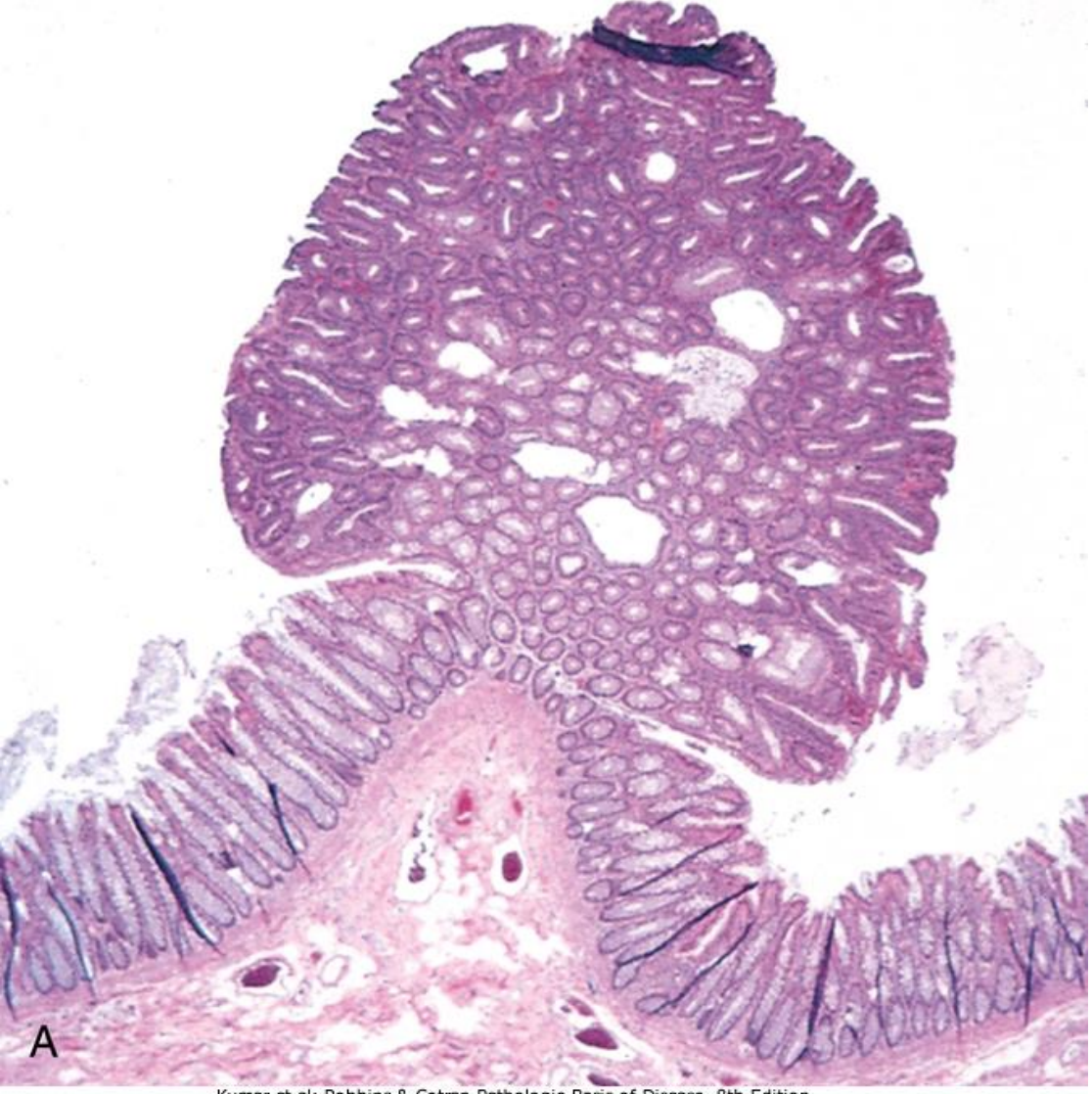

Kumar et al: Robbins & Cotran Pathologic Basis of Disease, 8th Edition.
Copyright © 2009 by Saunders, an imprint of Elsevier, Inc. All rights reserved.

Kumar et al: Robbins & Cotran Pathologic Basis of Disease, 8th Edition.
Copyright © 2009 by Saunders, an imprint of Elsevier, Inc. All rights reserved.

Colonic polyp. **A,** This benign glandular tumor (adenoma) is projecting into the colonic lumen and is attached to the mucosa by a distinct stalk. **B,** Gross appearance of several colonic polyps.

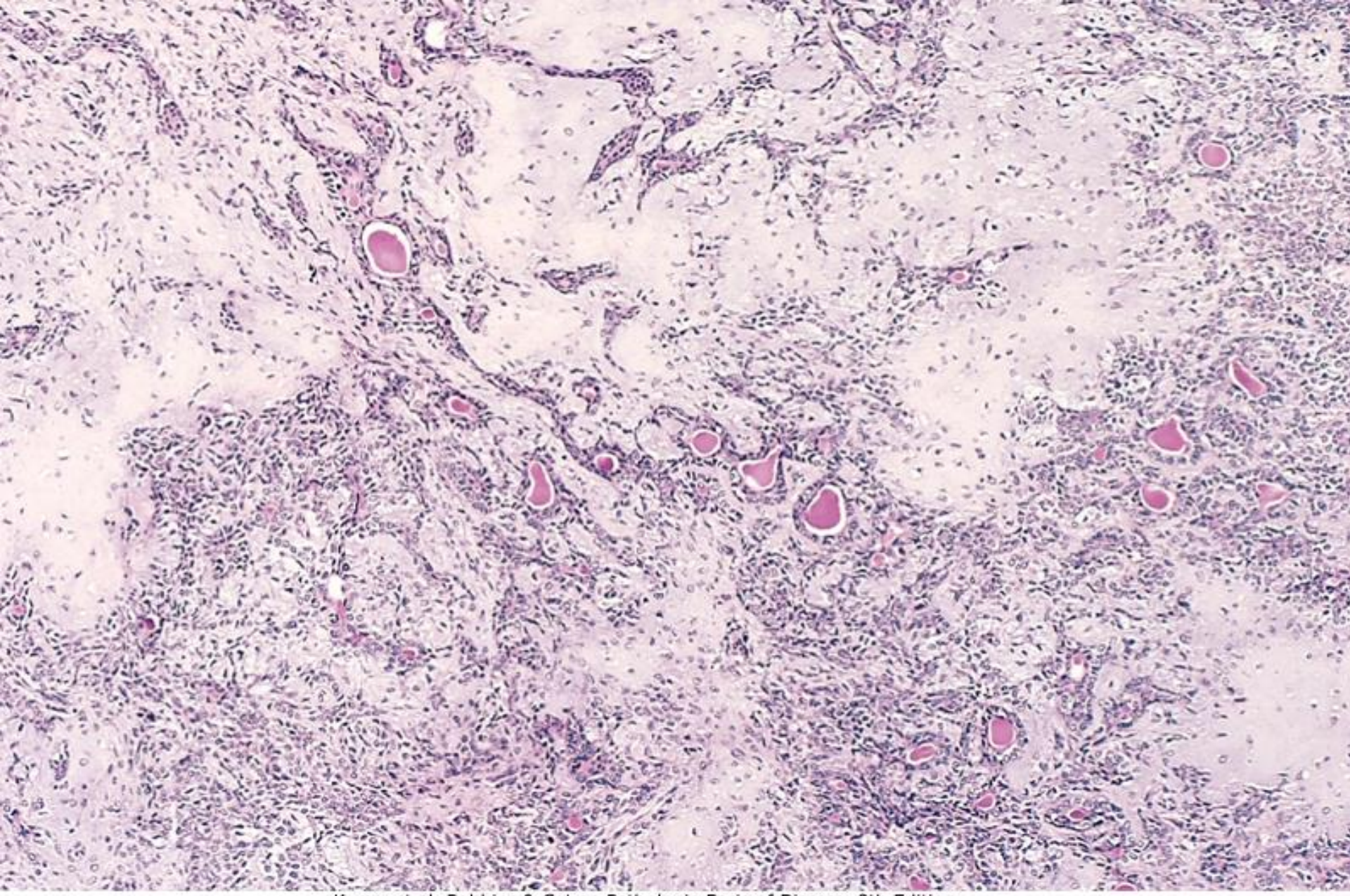

Kumar et al: Robbins & Cotran Pathologic Basis of Disease, 8th Edition.
Copyright © 2009 by Saunders, an imprint of Elsevier, Inc. All rights reserved.

Adenoma pleomórfico de glándula parótida

TUMORES MALIGNOS

Formados a partir de una capa embrionaria

- Origen: Tejidos mesenquimales ➡ Sarcomas
- Tejido epitelial (cualquiera de las 3 capas embrionarias) ➡ Carcinomas
    - ➡ patrón glandular ➡ Adenocarcinomas
    - ➡ epitelial ➡ Carcinoma escamoso

Formados por varios células totipotenciales (mas de una capa embrionaria)

- Teratoma

Tissue of Origin	Benign	Malignant
COMPOSED OF ONE PARENCHYMAL CELL TYPE		
Tumors of Mesenchymal Origin		
Connective tissue and derivatives	Fibroma	Fibrosarcoma
	Lipoma	Liposarcoma
	Chondroma	Chondrosarcoma
	Osteoma	Osteogenic sarcoma
Endothelial and Related Tissues		
Blood vessels		
Lymph vessels	Lymphangioma	Lymphangiosarcoma
Synovium		Synovial sarcoma
Mesothelium		Mesothelioma
Brain coverings	Meningioma	Invasive meningioma
Blood Cells and Related Cells		
Hematopoietic cells		Leukemias
Lymphoid tissue		Lymphomas
Muscle		
Smooth	Leiomyoma	Leiomyosarcoma
Striated	Rhabdomyoma	Rhabdomyosarcoma

Tumors of Epithelial Origin		
Stratified squamous	Squamous cell papilloma	Squamous cell carcinoma
Basal cells of skin or adnexa		Basal cell carcinoma
Epithelial lining of glands or ducts	Adenoma	Adenocarcinoma
	Papilloma	Papillary carcinomas
	Cystadenoma	Cystadenocarcinoma
Respiratory passages	Bronchial adenoma	Bronchogenic carcinoma
Renal epithelium		
Liver cells	Liver cell adenoma	Hepatocellular carcinoma
Urinary tract epithelium (transitional)	Transitional-cell papilloma	Transitional-cell carcinoma
Placental epithelium	Hydatidiform mole	Choriocarcinoma
Testicular epithelium (germ cells)		Seminoma
		Embryonal carcinoma
Tumors of Melanocytes	Nevus	Malignant melanoma
MORE THAN ONE NEOPLASTIC CELL TYPE-MIXED TUMORS, USUALLY DERIVED FROM ONE GERM CELL LAYER		
Salivary glands	Pleomorphic adenoma (mixed tumor of salivary origin)	Malignant mixed tumor of salivary gland origin
Renal anlage		Wilms tumor
MORE THAN ONE NEOPLASTIC CELL TYPE DERIVED FROM MORE THAN ONE GERM CELL LAYER-TERATOGENOUS		
Totipotential cells in gonads or in embryonic rests	Mature teratoma, dermoid cyst	Immature teratoma, teratocarcinoma

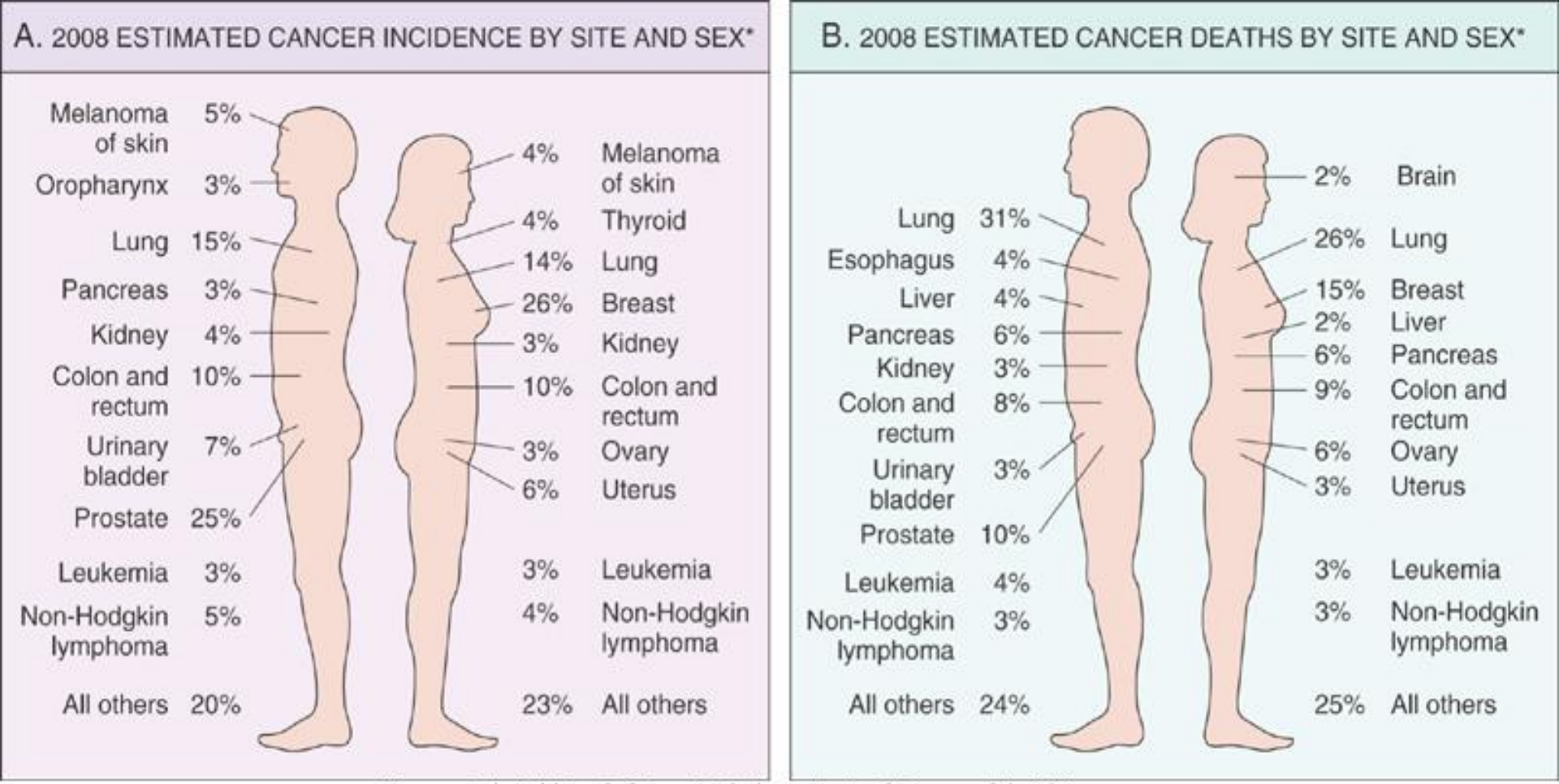

Kumar et al: Robbins & Cotran Pathologic Basis of Disease, 8th Edition.
Copyright © 2009 by Saunders, an imprint of Elsevier, Inc. All rights reserved.

Cancer incidence and mortality by site and sex. Excludes basal cell and squamous cell skin cancers and in situ carcinomas, except urinary bladder. (Adapted from Jemal A et al.: Cancer statistics, 2008. CA Cancer J Clin 58:2, 2008.)

CARACTERISTICAS DE LAS NEOS BENIGNAS/MALIGNAS

- Diferenciación y anaplasia
- Velocidad de crecimiento: 30 duplicaciones poblacionales para producir 10^9 (1gm) y 10 mas para 10^{12} (1Kg)
- Invasión local
- Metástasis

CARACTERISTICAS DE LAS NEOPLASIAS MALIGNAS

- ANAPLASIA: CARENCIA DE DIAFERENCIACION, CELULAS GIGANTES
- PLEOMORFISMO: VARIACION EN TAMAÑO Y FORMA
- MORFOLOGIA NUCLEAR ANORMAL: HIPERCROMATISMO
- MITOSIS
- PERDIDA DE POLARIDAD
- NECROSIS

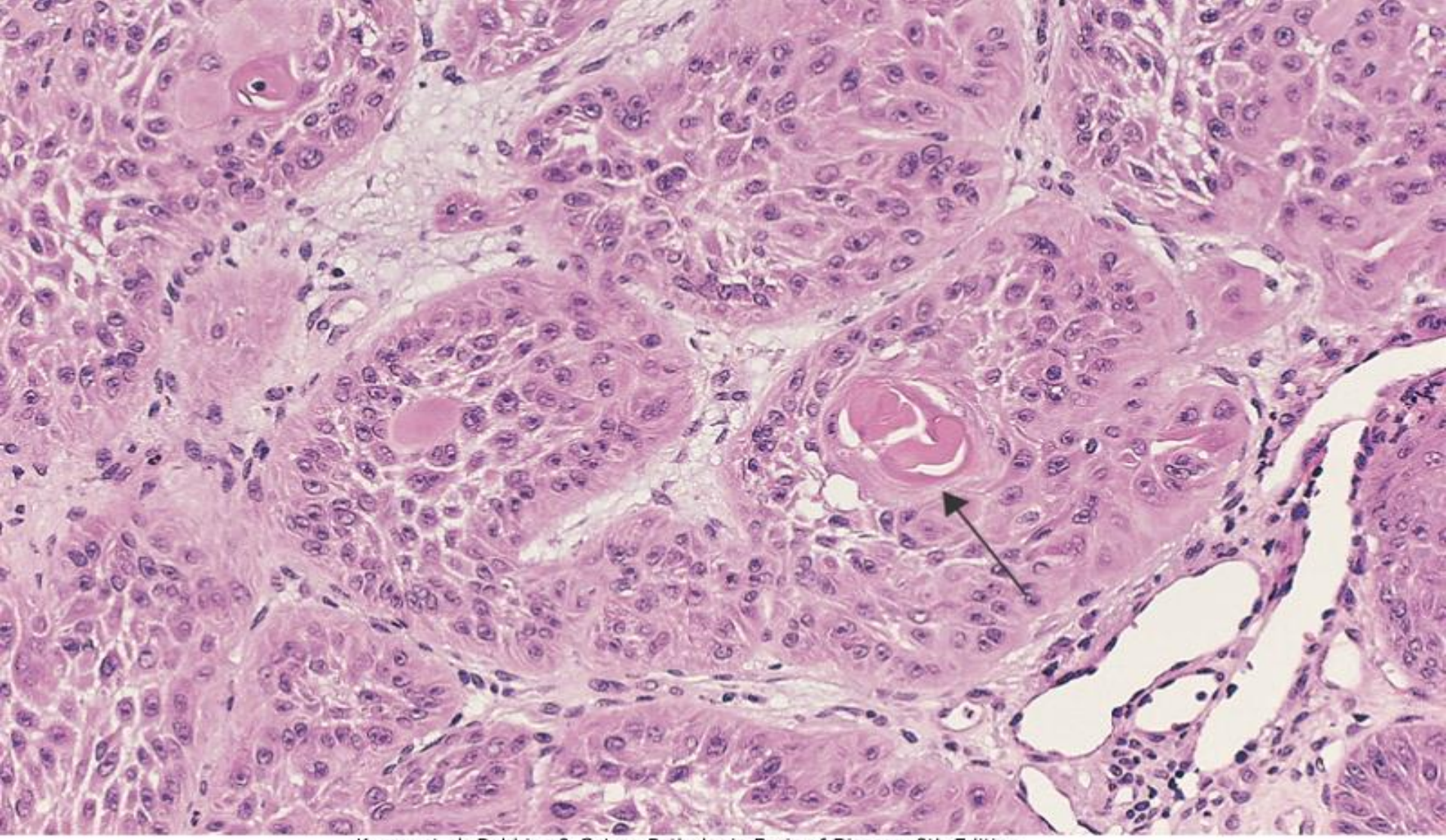

Kumar et al: Robbins & Cotran Pathologic Basis of Disease, 8th Edition.
Copyright © 2009 by Saunders, an imprint of Elsevier, Inc. All rights reserved.

Well-differentiated squamous cell carcinoma of the skin. The tumor cells are strikingly similar to normal squamous epithelial cells, with intercellular bridges and nests of keratin pearls *(arrow).* (Courtesy of Dr. Trace Worrell, University of Texas Southwestern Medical School, Dallas, TX.)

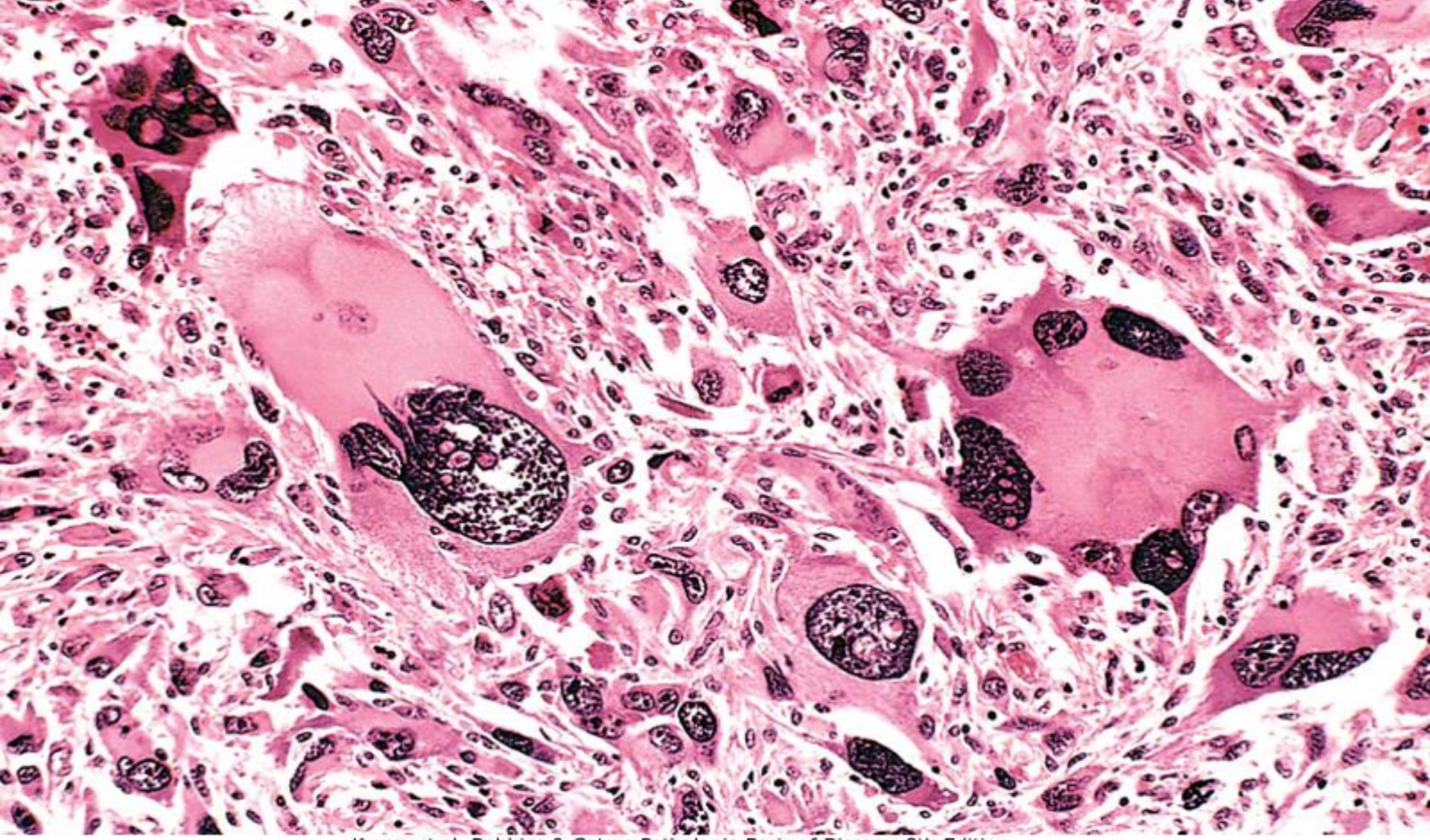

Kumar et al: Robbins & Cotran Pathologic Basis of Disease, 8th Edition.
Copyright © 2009 by Saunders, an imprint of Elsevier, Inc. All rights reserved.

Anaplastic tumor of the skeletal muscle (rhabdomyosarcoma). Note the marked cellular and nuclear pleomorphism, hyperchromatic nuclei, and tumor giant cells. (Courtesy of Dr. Trace Worrell, University of Texas Southwestern Medical School, Dallas, TX.)

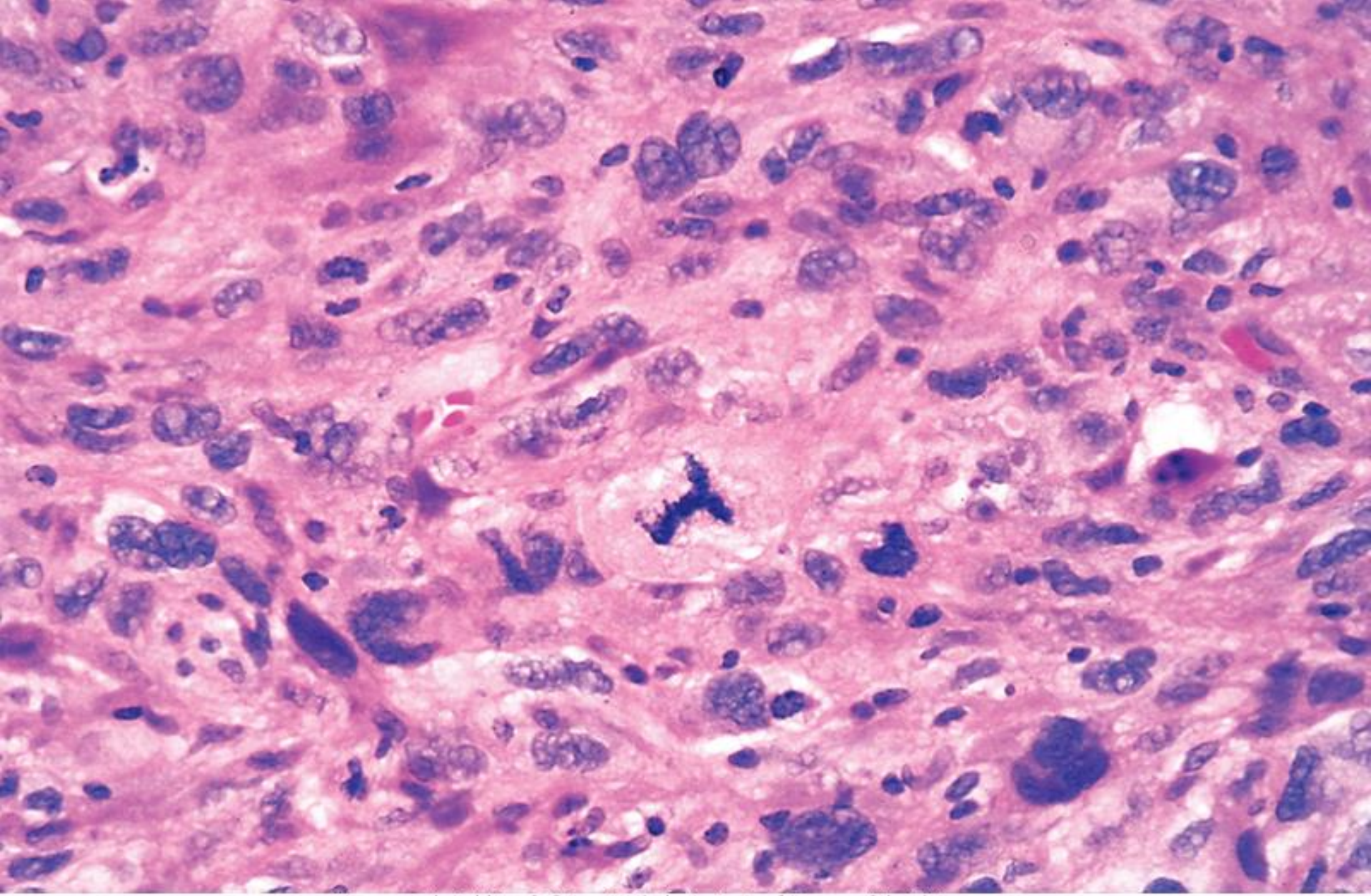

Kumar et al: Robbins & Cotran Pathologic Basis of Disease, 8th Edition.
Copyright © 2009 by Saunders, an imprint of Elsevier, Inc. All rights reserved.

Anaplastic tumor showing cellular and nuclear variation in size and shape. The prominent cell in the center field has an abnormal tripolar spindle.

GRADOS Y ESTADIAJE

- LOS METODOS PARA CUANTIFICAR LA AGRESIVIDAD DE UNA NEOPLASIA DETERMINADA, SU APARENTE EXTENSION Y DISEMINACION EN EL PACIENTE SON NECESARIAS PARA DETERMINAR EL PRONÓSTICO Y PARA COMPARAR LOS RESULTADOS FINALES DE PROTOCOLOS ESTABLECIDOS.

TIROIDES NORMAL

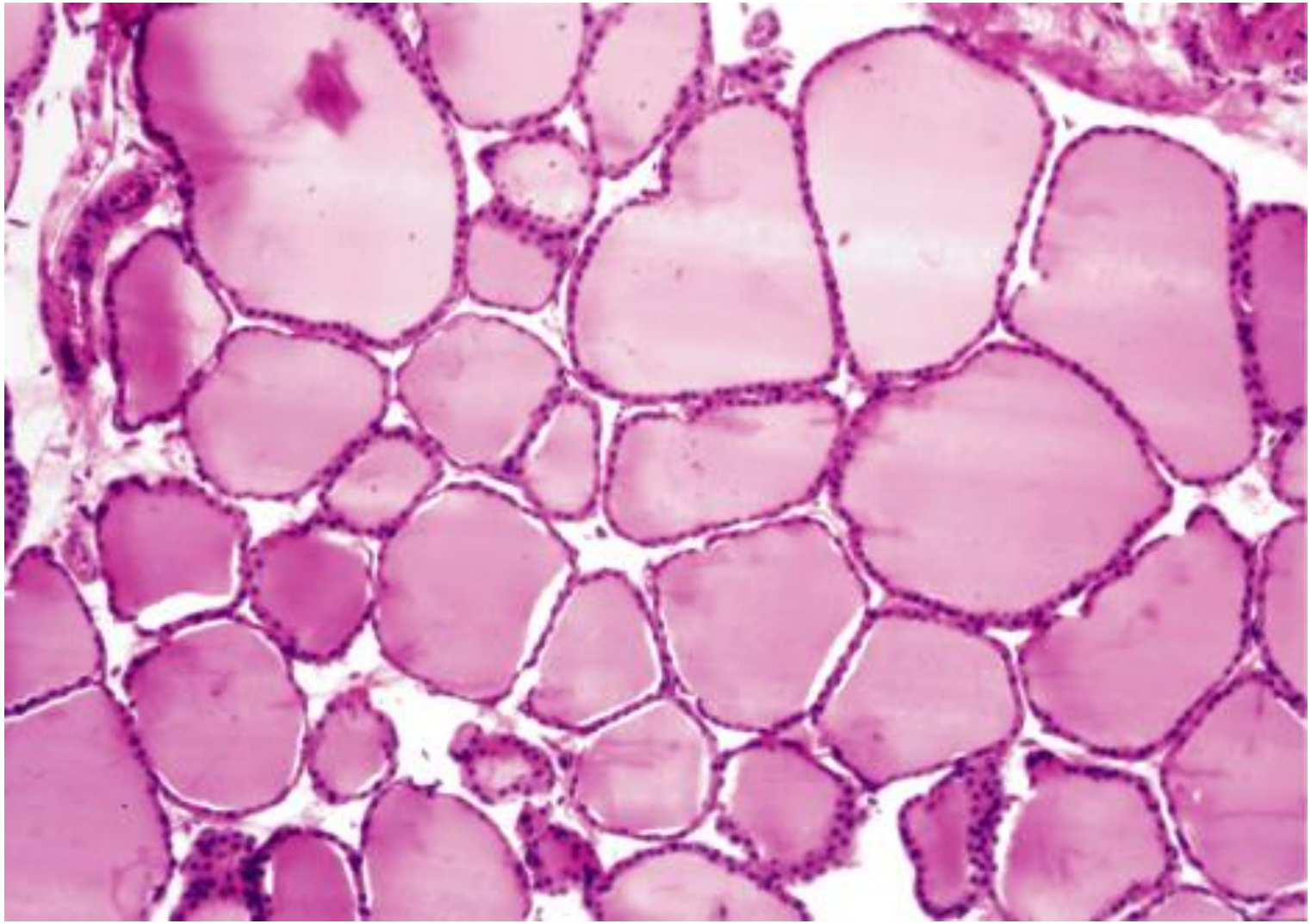

CARCINOMA FOLICULAR

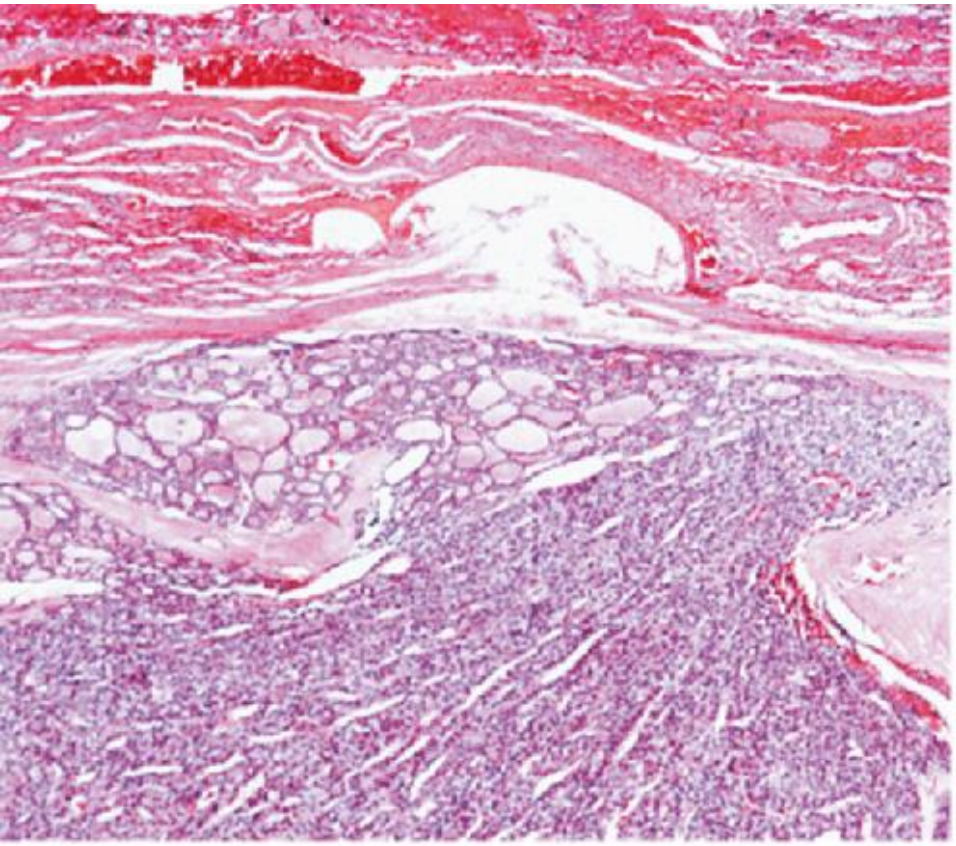

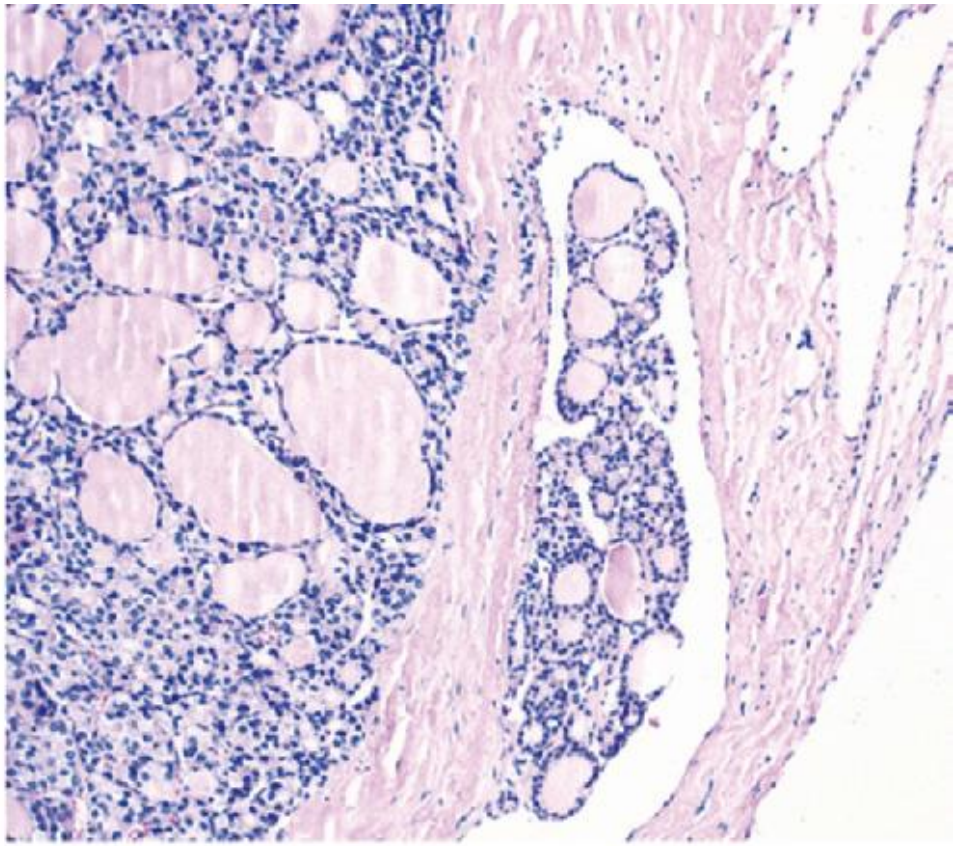

CARCINOMA INDIFERENCIADO DE TIROIDES

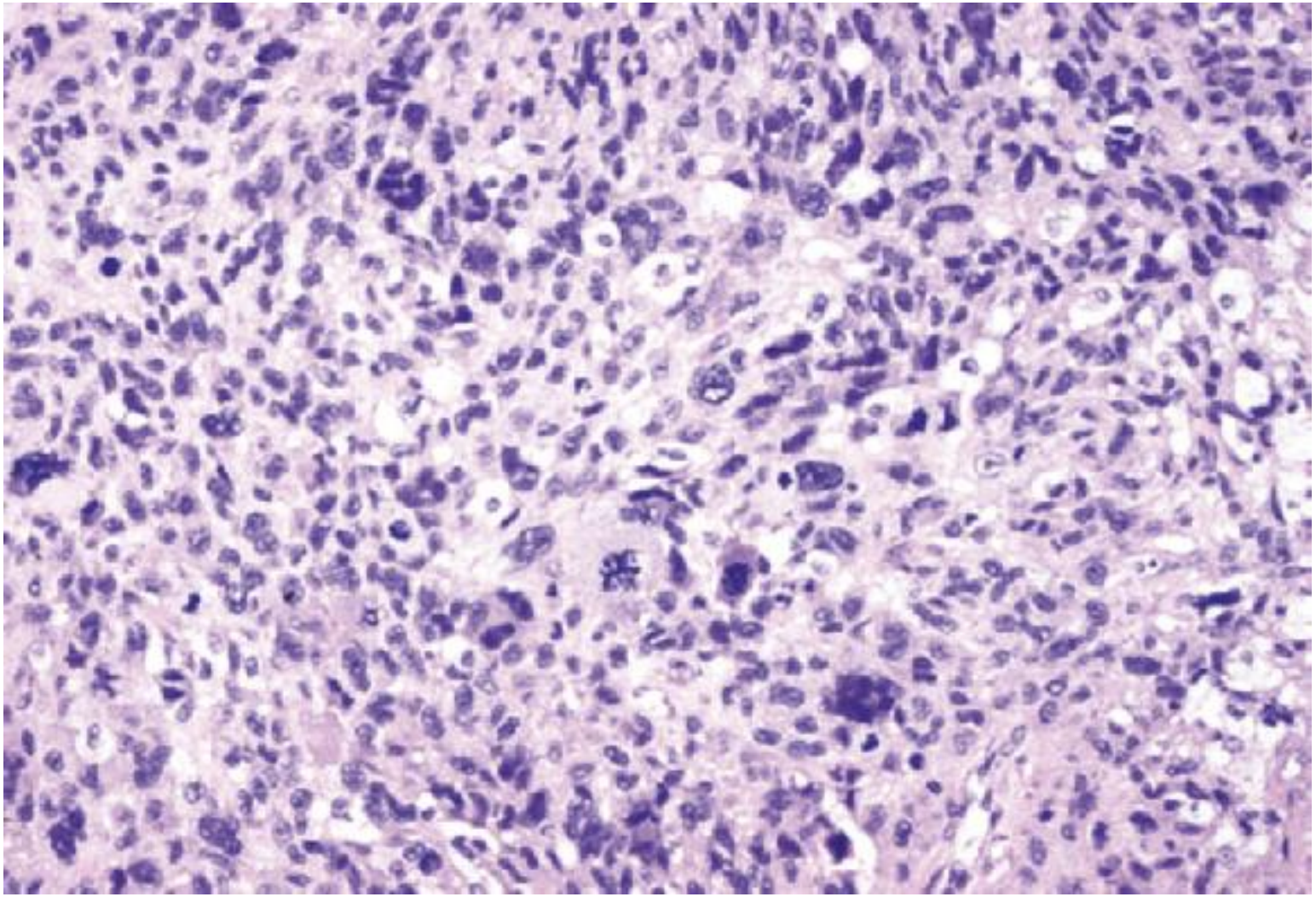

GRADO DE UNA NEOPLASIA MALIGNA

- ES BASADO EN EL GRADO DE DIFERNCIACION DE LAS CELULAS TUMORALES.
- EN ALGUNOS CASOS EN EL NUMERO DE MITOSIS Y CARACTERISTICAS ARQUITECTURALES.
- GENERALMENTE VAN DE DOS CATEGORIAS A CUATRO.
- TIENE MENOR RELEVANCIA CLINICA QUE EL ESTADIAJE.

CARCINOMA DUCTAL DE MAMA DE BAJO GRADO

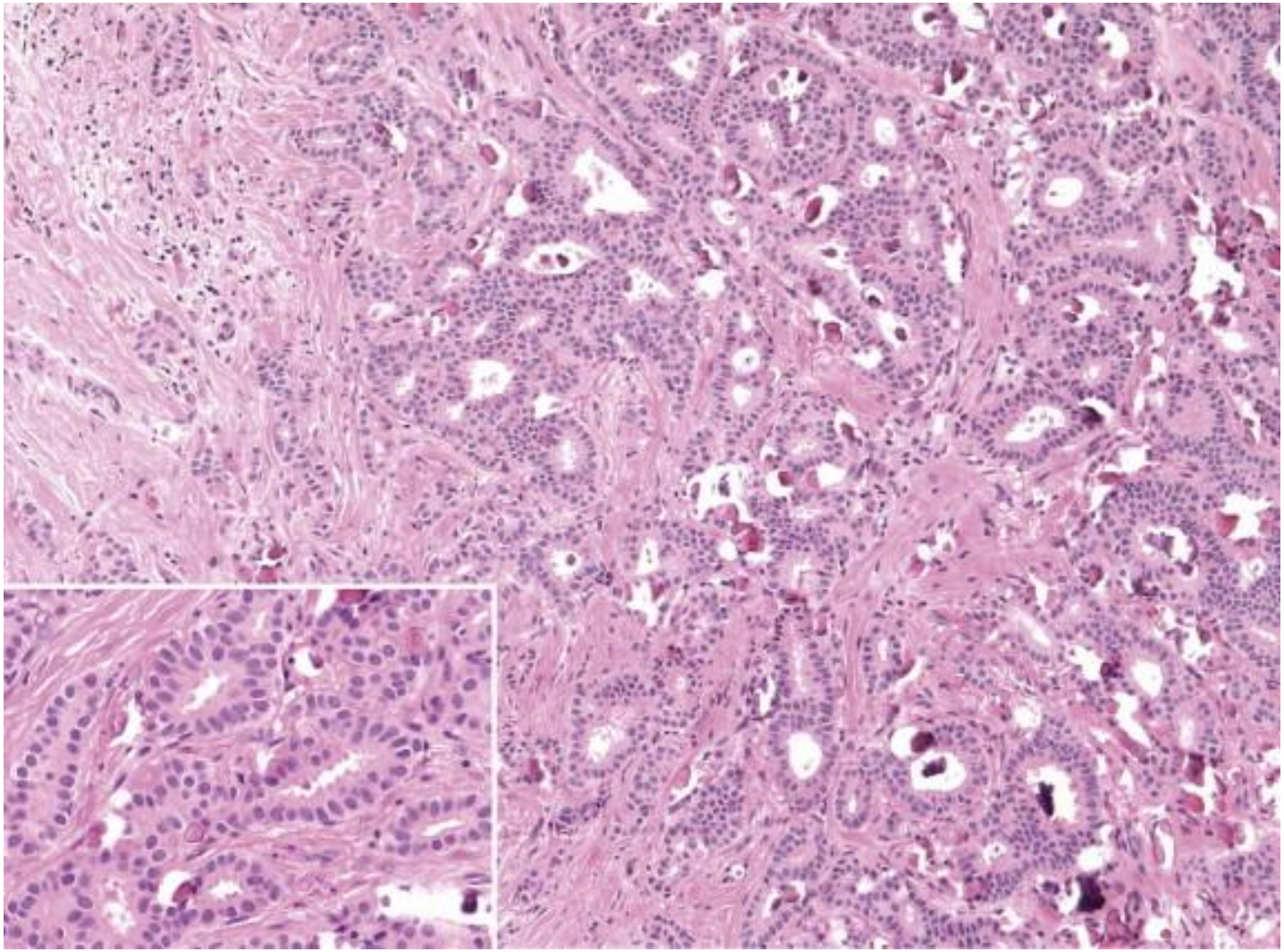

CARCINOMA DUCTAL DE MAMA DE ALTO GRADO HISTOLOGICO

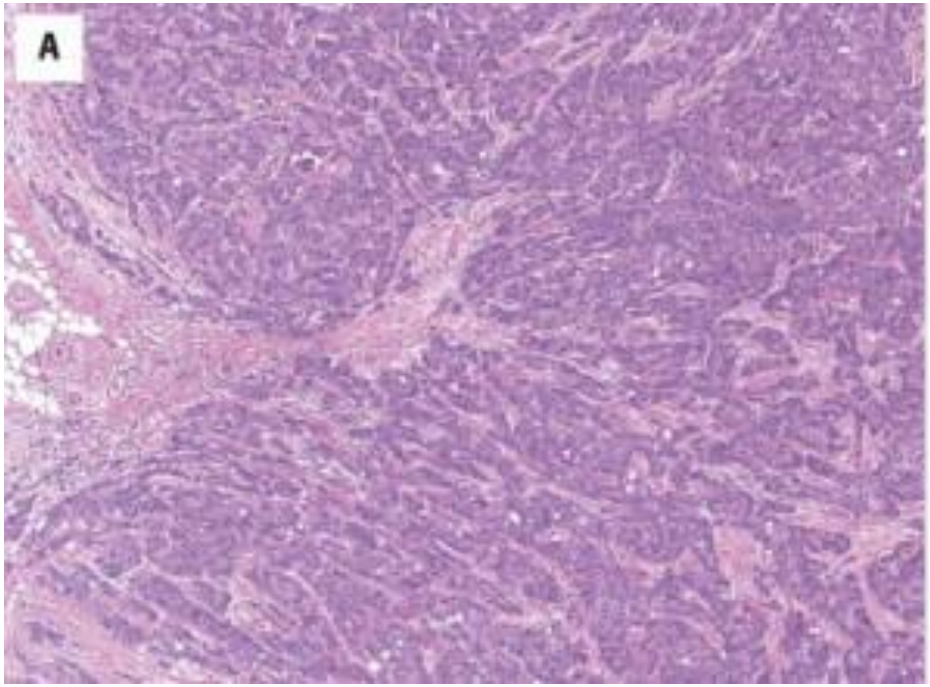

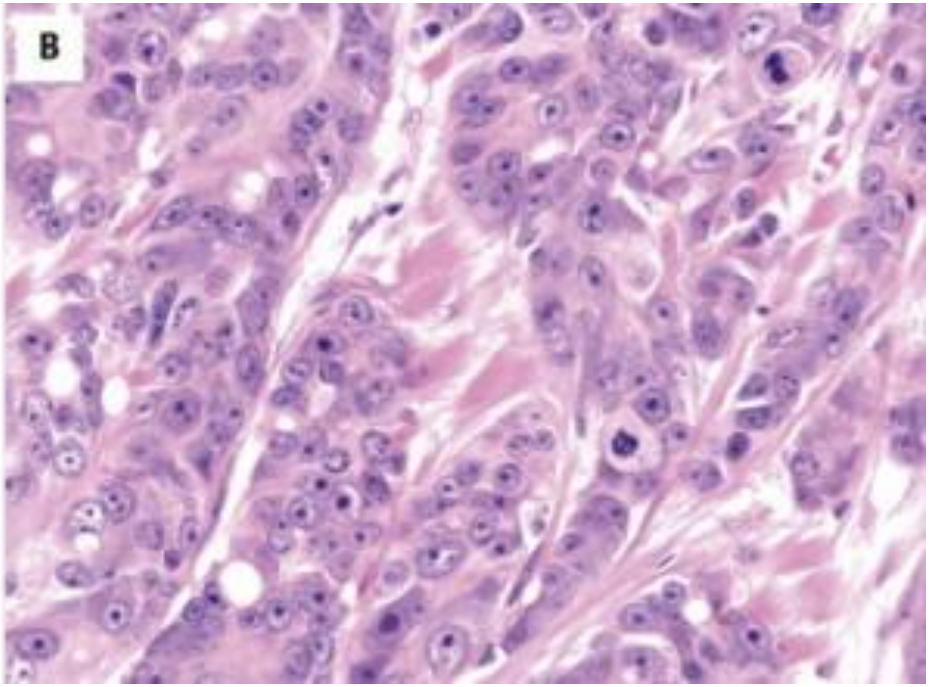

ESTADIAJE

EL ESTADIAJE DEL CANCER ES BASADO EN:

- EL TAMAÑO DE LA LESION PRIMARIA,
- LA EXTENSION DE LA DISEMINACION A GANGLIOS LINFATICOS REGIONALES, Y
- LA PRESENCIA O AUSENCIA DE METASTASIS.

LA MAS UTILIZADA ACTUALMENTE ES LA DE LA **AMERICAN JOINT COMMITTEE ON CANCER STAGING: TNM**

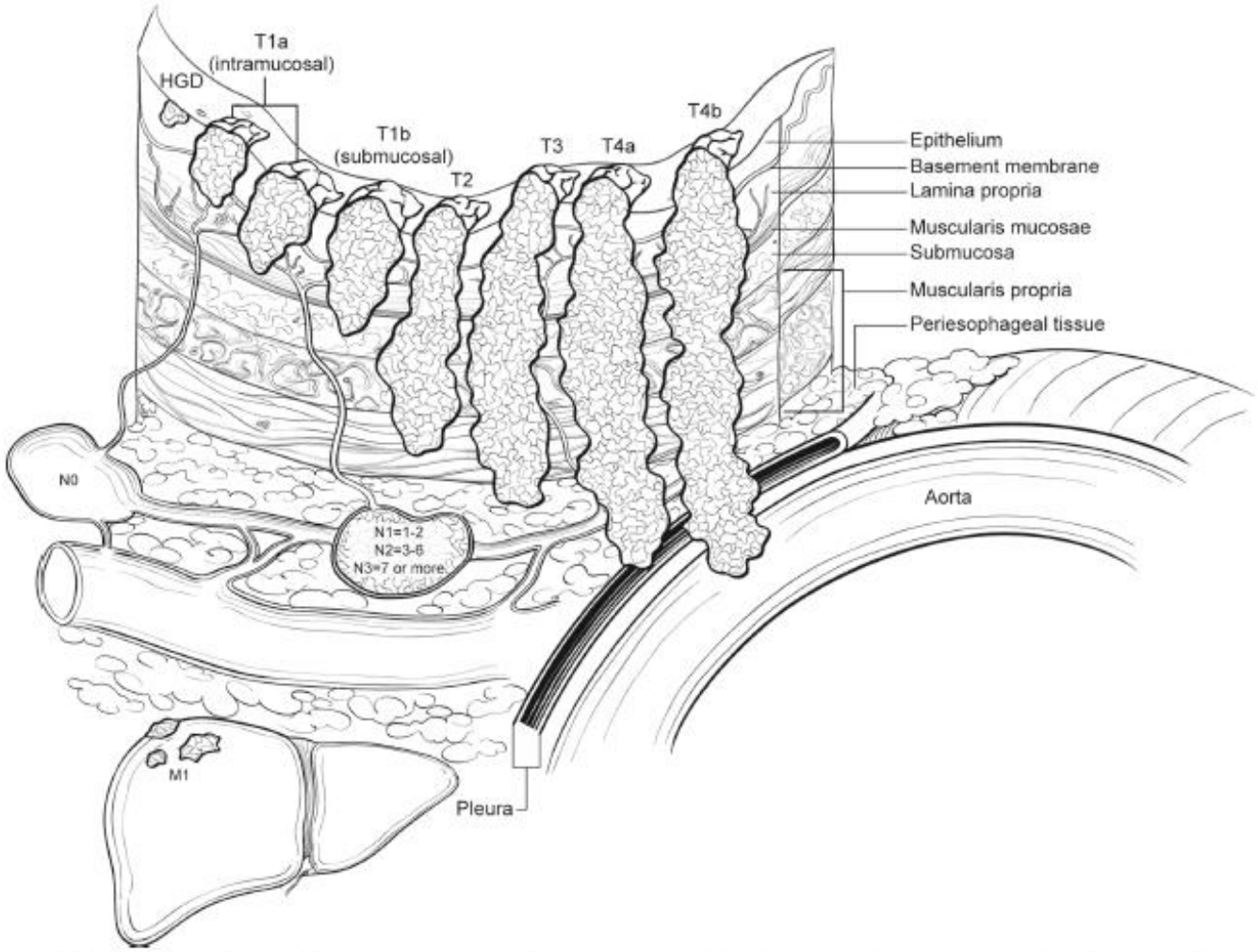

FIGURE 10.5. T, N, and M classifications. Primary tumor (T) is classified by depth of tumor invasion. Regional lymph node classifications are determined by metastatic burden. Distant metastatic sites are designated M1.

ASPECTOS CLINICOS DEL CANCER

- AUNQUE LOS TUMORES MALIGNOS AMENAZAN MAS LA VIDA, CUALQUIER TUMOR PUEDE CAUSAR MORBILIDAD Y MORTALIDAD.
- TANTO LOS TUMORES MALIGNOS COMO BENIGNOS PUEDEN CAUSAR PROBLEMAS POR:

  A) LOCALIZACION Y COMPROMISO DE ESTRUCTURAS ADYACENTES.

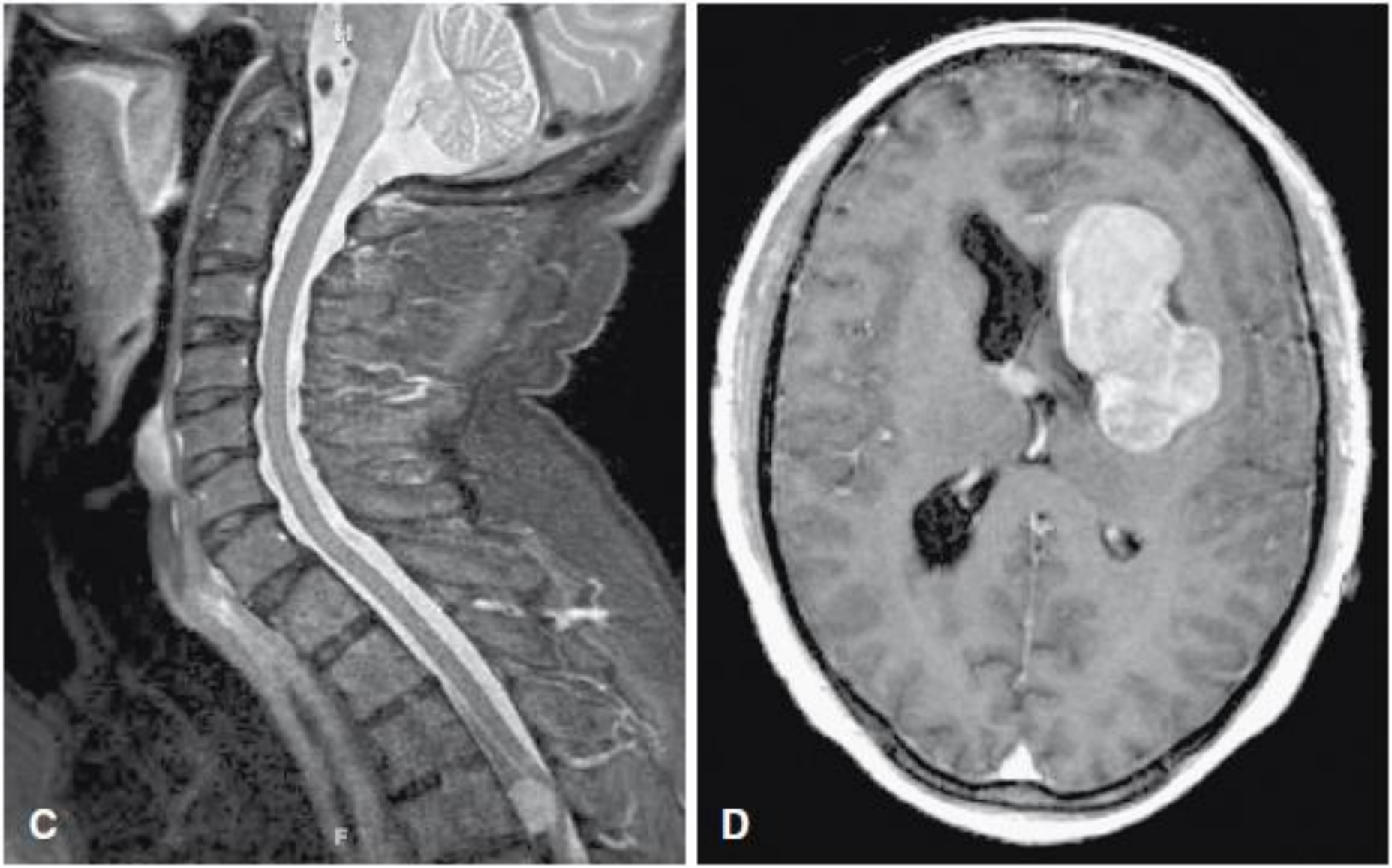
C
D

- ACTIVIDAD FUNCIONAL TAL COMO SINTESIS DE HORMONAS O EL DESARROLLO DE SINDROMES PARANEOPLASICOS.

Clinical Syndromes	Major Forms of Underlying Cancer	Causal Mechanism
ENDOCRINOPATHIES		
Cushing syndrome	Small-cell carcinoma of lung	ACTH or ACTH-like substance
	Pancreatic carcinoma	
	Neural tumors	
Syndrome of inappropriate antidiuretic hormone secretion	Small-cell carcinoma of lung; intracranial neoplasms	Antidiuretic hormone or atrial natriuretic hormones
Hypercalcemia	Squamous cell carcinoma of lung	Parathyroid hormone–related protein (PTHRP), TGF-α, TNF, IL-1
	Breast carcinoma	
	Renal carcinoma	
	Adult T-cell leukemia/lymphoma	
Hypoglycemia	Ovarian carcinoma	
	Fibrosarcoma	Insulin or insulin-like substance
	Other mesenchymal sarcomas	
Carcinoid syndrome	Hepatocellular carcinoma	
	Bronchial adenoma (carcinoid)	Serotonin, bradykinin
	Pancreatic carcinoma	
Polycythemia	Gastric carcinoma	
	Renal carcinoma	Erythropoietin
	Cerebellar hemangioma	
	Hepatocellular carcinoma	

NERVE AND MUSCLE SYNDROMES		
Myasthenia	Bronchogenic carcinoma	Immunological
Disorders of the central and peripheral nervous system	Breast carcinoma	
DERMATOLOGIC DISORDERS		
Acanthosis nigricans	Gastric carcinoma Lung carcinoma Uterine carcinoma	Immunological; secretion of epidermal growth factor
Dermatomyositis	Bronchogenic, breast carcinoma	Immunological
OSSEOUS, ARTICULAR, AND SOFT-TISSUE CHANGES		
Hypertrophic osteoarthropathy and clubbing of the fingers	Bronchogenic carcinoma	Unknown
VASCULAR AND HEMATOLOGIC CHANGES		
Venous thrombosis (Trousseau phenomenon)	Pancreatic carcinoma Bronchogenic carcinoma Other cancers	Tumor products (mucins that activate clotting)
Nonbacterial thrombotic endocarditis	Advanced cancers	Hypercoagulability
Red cell aplasia	Thymic neoplasms	Unknown
OTHERS		
Nephrotic syndrome	Various cancers	Tumor antigens, immune complexes

- SANGRADO E INFECCIONES CUANDO EL TUMOR SE ULCERA POR LA SUPERFICIE ADYACENTE

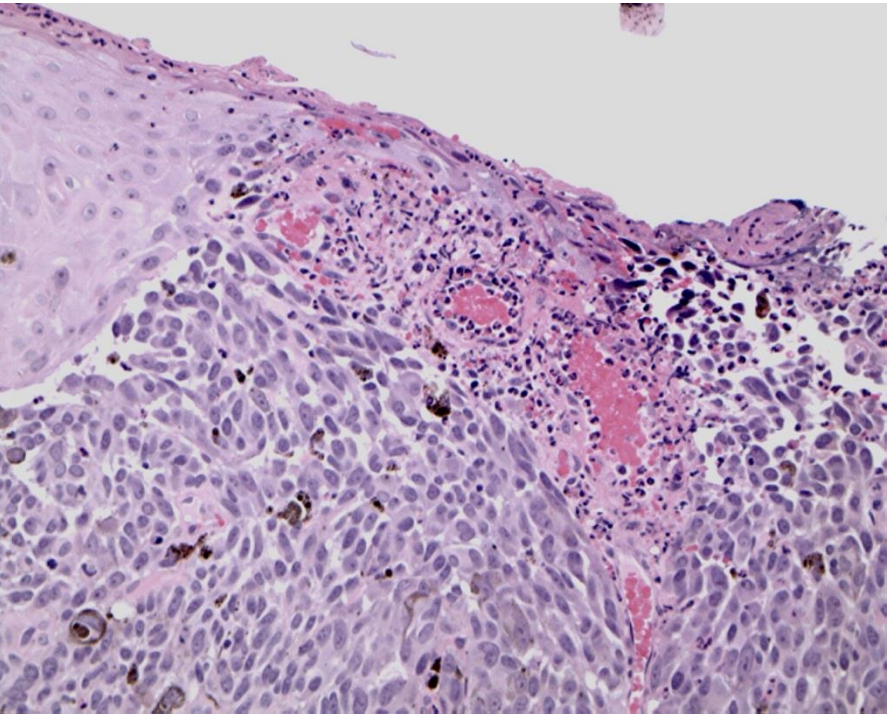

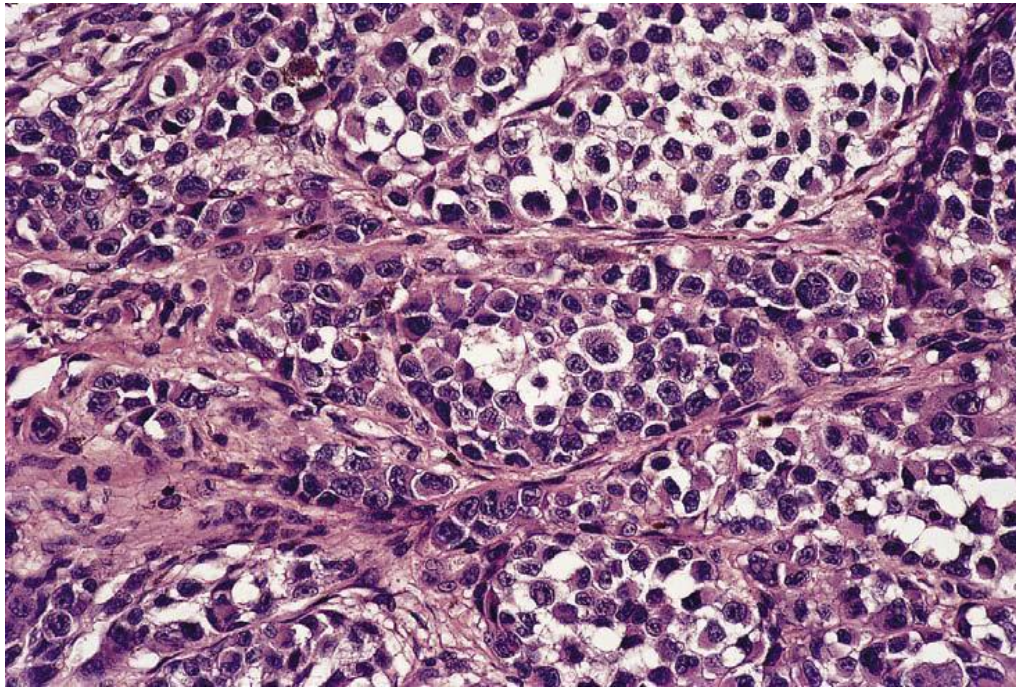

- SINTOMAS QUE RESULTAN DE RUPTURA E INFARTO.
- SINDROME CONSUNTIVO Y CAQUEXIA.

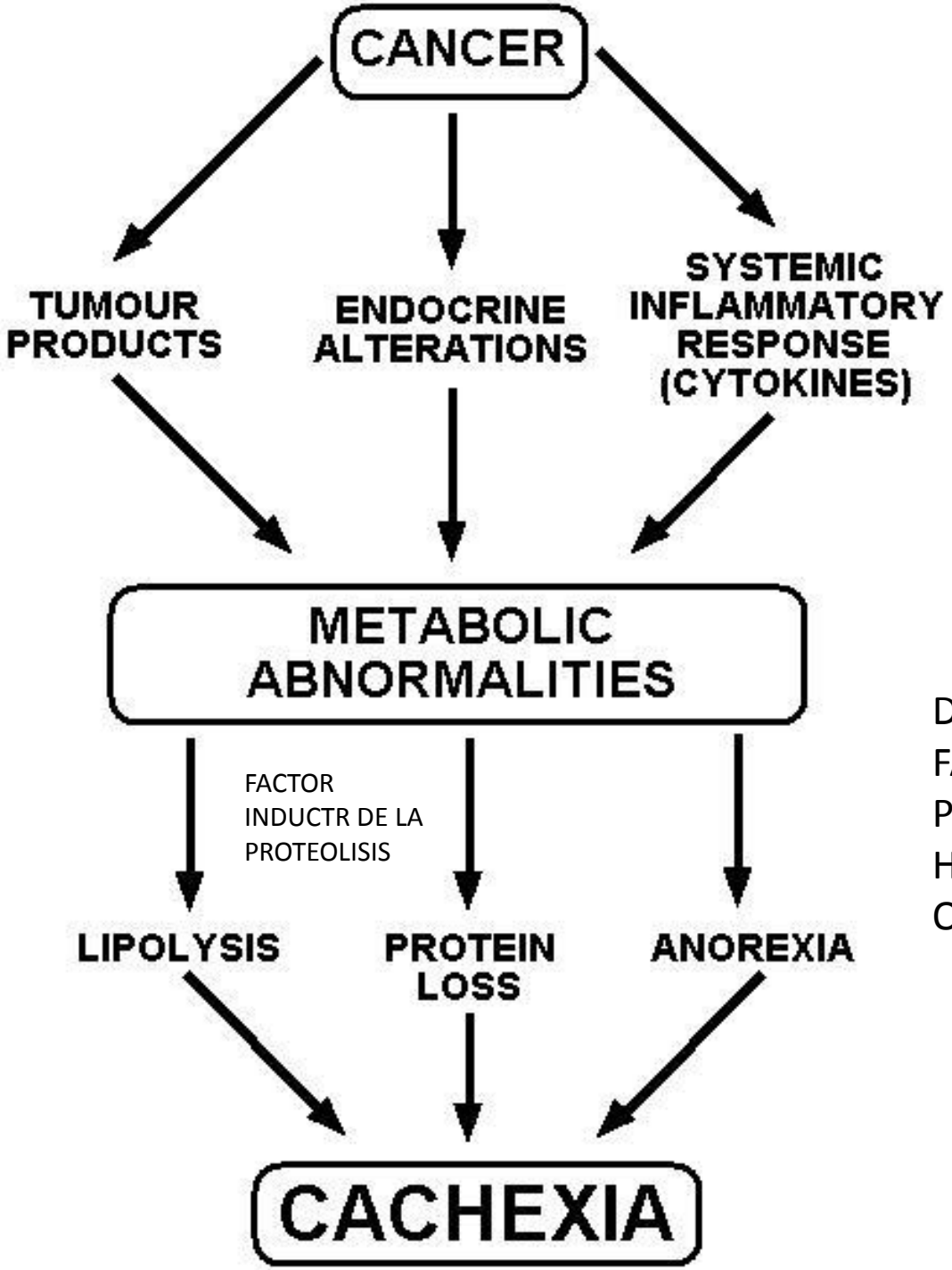

FACTOR DE NECROSIS TUMORAL

DISBALANCE IGF, FACTOR QUE PROMUEVE LA HIPERTROFIA Y OPUESTOS

CASCADA METASTASICA

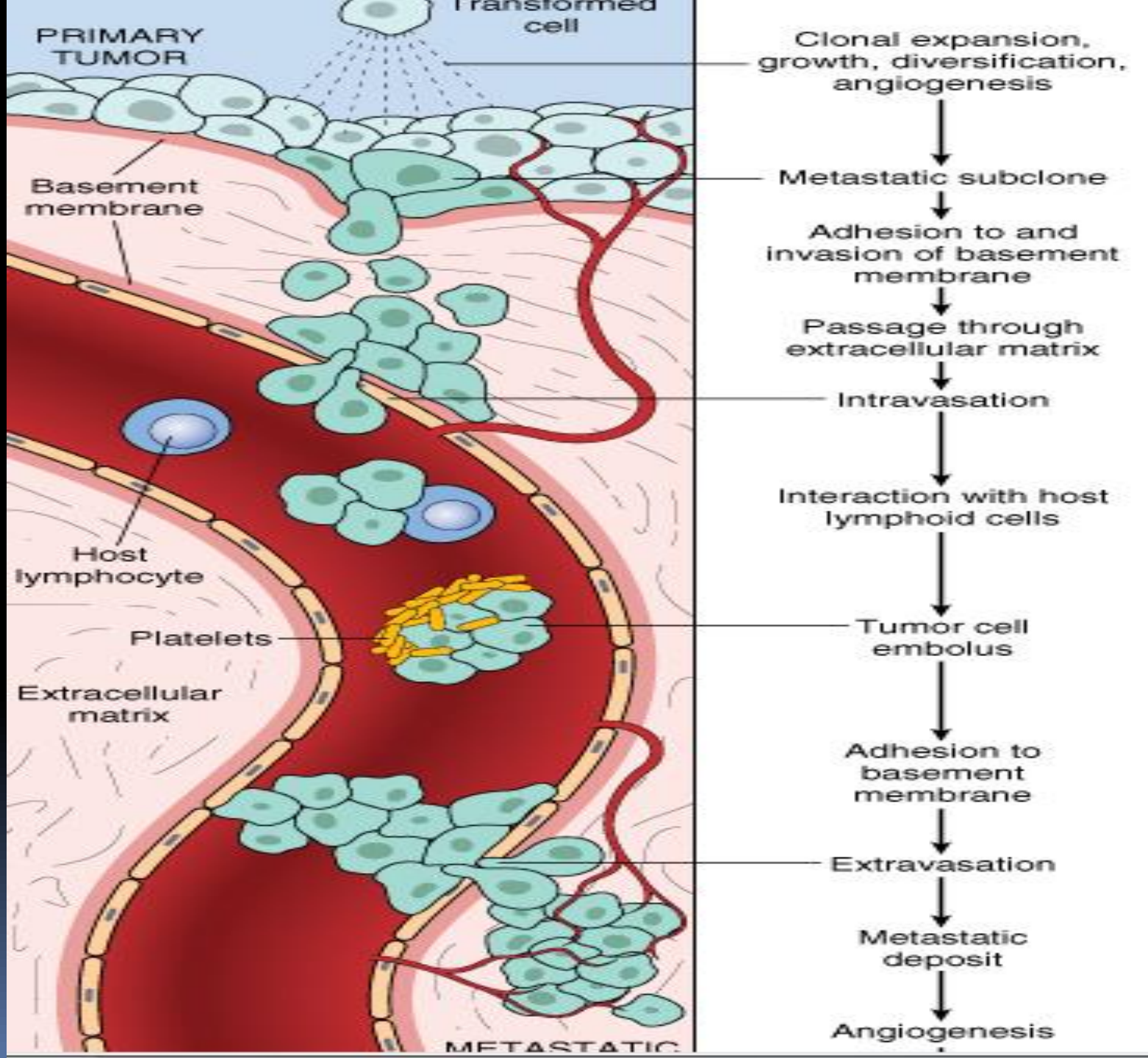

GRACIAS